

A complex case study reviewing care of a patient with cellulitis caused by lymphoedema

Jane Cadogan, Tissue Viability Nurse, Swindon PCT. Joanne Waldron, Vascular Nurse, Great Western Hospital, Swindon.

Introduction

The 36-year-old patient in this case study (Mrs P) was suffering and distressed due to cellulitis and tissue loss resulting from a primary lymphoedema condition called Milroy's disease.

This disease is an inherited condition which appears soon after birth and is usually caused by aplasia of the lymphatics (Mortimer 1996). Mrs P found it increasingly difficult to lose the weight gained after the birth of her daughter three years ago, and her problems were further complicated by asthma. This paper describes the care provided in order to reduce lymphoedema and enhance healing of her wounds.

The patient with lymphoedema becomes increasingly immobile and the affected limb is often in a permanently dependent position causing venous hypertension and resultant overloading of the failing lymphatics (Vaqa & Ryan, 2003). Loss of barrier function encourages penetration of bacteria and stimulates repair mechanisms that generate cytokines, which, in turn lead to inflammation (Vaqa & Ryan, 2003) and this largely explains why Mrs P acquired cellulitis in her legs. Until recently, the relationship between wound healing and the negative effects of associated peri-wound lymphoedema has received little attention (Macdonald et al. 2003) although the associated literature is now increasing.

Treatment

The mobilization of lymph fluid from the peri-wound area with the use of reasoned compression is essential for proper therapy of the open wound (Macdonald et al. (2003) and the mainstay of lymphoedema management is physical decongestive treatment (Hampton 2003). Therefore, compression therapy is of prime importance.

The case study

Mrs P was admitted to an acute ward at Princess Margaret Hospital, Swindon on 1/12/02. She weighed 39 stone on admission and her Hb was 13 with a WBC of 7.10. Her albumin levels were 34. As her weight was greater than 25 stone, she required a specialist bed and the KCI low air loss BariAir therapy bed was selected as this was designed to support the larger patient and had an integral mattress system. She was commenced on IV Clinomyocin with Morphine for analgesia. 24 hours later, the antibiotics were changed to IV Teicoplanin.

At this point, pain was a problem and this was helped through administration of entinox (for dressing change and movement), 4-hourly oral morphine and paracetamol 1g QDS as recommended by the pain team. In the past she had been managed by the hospital specialist lymphoedema team who had assessed her vascular status and reduced the swelling with bandages, and as there were no open wounds, the treatment had usually been effective.

By the 4/12/02, Mrs Pierce was referred to the Tissue Viability Nurse (TVN). Assessment showed blisters on the left leg and foot with some tissue loss (Picture 2) which discharged copious amounts of exudate. Cavilon was applied to protect the good skin and an emollient was applied to the rest of the leg. Sorbsan Plus and absorbent padding were placed underneath the leg to contain exudate. The following day, her Hb had decreased to 10.6 and her WBC increased to 18.2. There was some concern about her fluid loss as the albumin level had also dropped to 29.

On the 13/12/02 the left leg wounds were treated with Vacutex as the dressing, in order to absorb the wound fluid. On the 19/12/02 sharp debridement was performed and V.A.C.® Therapy was commenced using ATS (Advanced Therapy System). This was expected to complete debridement and absorb fluid.

The TVN also commenced short-stretch compression therapy over a layer of specialist foam as it is recommended for lymphoedema (Penzer, 2003). The TVN also commenced short-stretch compression therapy using specialist foam to assist with reshaping the leg and filling in the deep creases, and wool padding to protect the skin. Short stretch bandages are recommended for lymphoedema as they provide a semi-rigid casing which creates pressure on the soft tissues during movement (Penzer, 2003). This variation in tissue pressure stimulates lymph drainage (Penzer, 2003). However, traditional cotton bandages tended to slip when the oedema was reduced. To overcome this problem the TVN decided to try a cohesive bandage. Actico cohesive short stretch bandages remained in tact even though the limb circumference was drastically reduced.

These were applied to the right leg to reduce the lymphoedema, but initially the left leg was too painful for compression. The Actico cohesive short-stretch bandages were applied from toe to knee and subsequent layers of Actico were applied in the opposite direction as recommended for larger legs. When the pain subsided in the left leg the bandages were applied to both legs to reduce limb oedema and the wounds on the left leg continued to heal.

As the limb was so large four bandages were required for each leg, and although spiral bandaging was attempted, it was not always possible due to the overlapping skin folds. It usually took two nurses two hours to complete bandaging her legs.

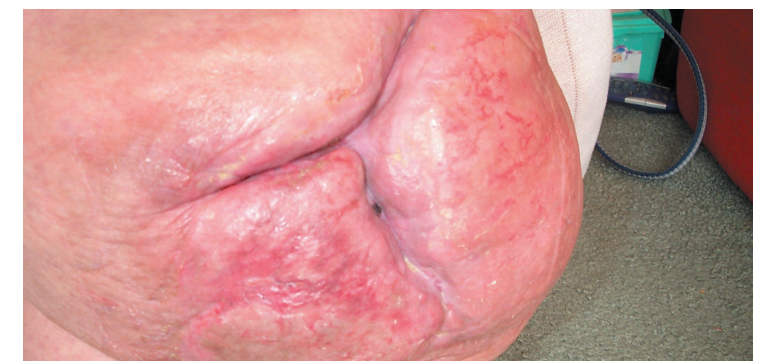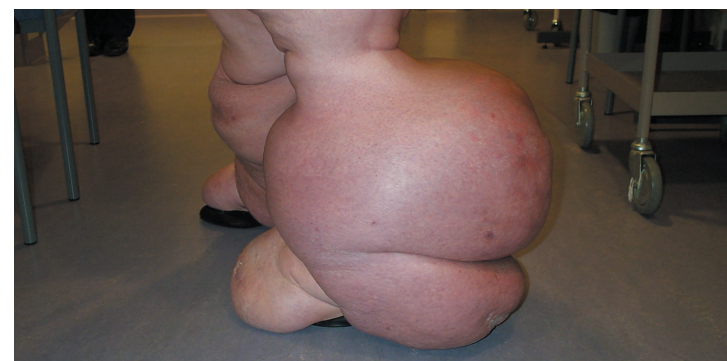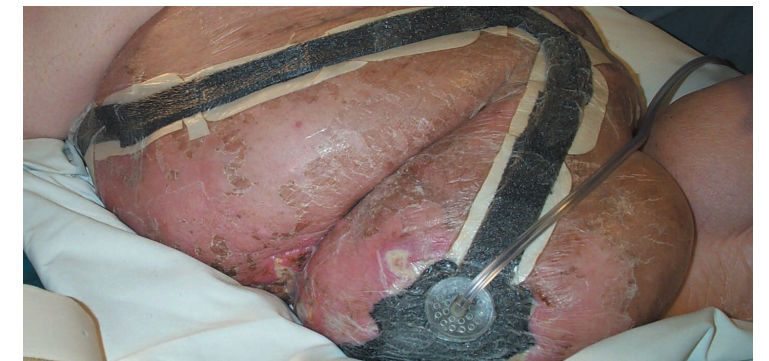
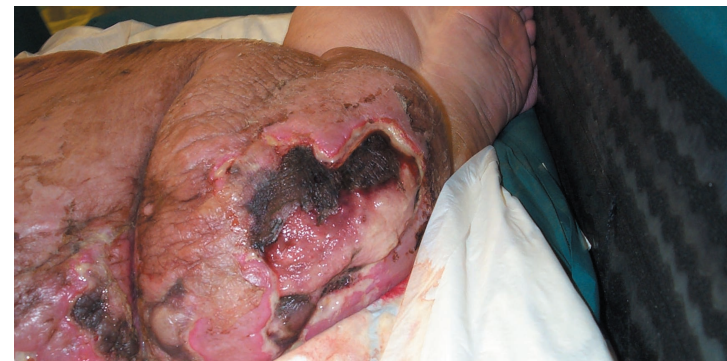By the 3/2/03 Mrs P left leg wound was 90% granulating and both legs had reduced significantly when she was discharged on 28/2/03. Mrs P returned to clinic on 4/4/03 when the wounds were fully healed (Picture 5). The right calf had reduced in size by 34cms with the area below the knee measuring 22cms less than on admission, and she was then able to wear made to measure hosiery.

Conclusion

The multiple challenges in the care of this complex case were solved by the combined expertise of the hospital vascular staff and the TVN, together with the use of many treatments to improve the quality of life for this patient. The high levels of exudate and the depth of her wounds were managed by the effective use of the V.A.C.®, thus reducing her pain and discomfort.

The Actico bandages had reduced the circumference of both limbs and this had an impact on the patient's lifestyle. Her husband no longer needed to come home at lunch time to assist her with bandaging as they stayed in place until the evening, and both legs were now small enough to use a CirCaid system. This gave her greater independence and increased self confidence.

Mrs P's lymphoedema will never be cured but the symptoms can be controlled to improve quality of life. The appropriate use of Actico cohesive short stretch bandages, the BariAir therapy system, V.A.C.® and CirCaid all provided the optimum wound healing environment and led to a positive outcome.



References

- Hampton S (2003) Elvarex compression garments in the management of lymphoedema. Br J Nurs. Aug 14-Sep 10;12(15):925-6, 928-9
- Macdonald JM, Sims N, Mayrovitz HN (2003) Lymphoedema, lipoedema, and the open wound: the role of compression therapy. Surg Clin North Am. Jun;83(3):639-58
- Mortimer PS. (1996) Lymphoedema. Vascular Surgery. The Medicine Group Journals Ltd. : 73-77
- Penzer, R. (2003) Lymphoedema. Nursing Standard. 17: (35) 45-51
- Vaqa B, Ryan TJ. (2003) Lymphoedema: Pathophysiology and management in resource-poor settings - relevance for lymphatic filariasis control programmes. Filaria J Mar 12;2(1):4.